

# Trauma Center Practice Management Guideline

*Blank Children's Hospital —Des Moines*

## *Choice of Imaging Modality*

### **PEDIATRICS**

Practice Management Guideline

Effective: 07/2017

Contact: Trauma Medical Director

Reviewed: 04/2026

### PECARN Pediatric Minor Head Injury CT Guidelines for Children Age **<2 YEARS**

- **GCS < 15**
- **Palpable skull fracture**
- **AMS** (agitation, somnolence, slow response, repetitive questioning)

**YES TO ANY**

**Head CT Indicated**  
High Risk: 4.4% risk of ci-TBI

**NO TO ALL**

- **Scalp hematoma (excluding frontal)**
- **LOC > 5 seconds**
- **Not acting normally per patient**
- **Severe mechanism of injury**
  - Fall > 3 ft
  - MVA w/ejection, rollover, or fatality
  - Bike/ped vs vehicle w/o helmet
  - Struck by high-impact object

**YES TO ANY**

**Observation vs CT using shared decision-making**  
Intermediate Risk: 0.9% risk of ci-TBI

**NO TO ALL**

**Head CT NOT Indicated**  
Low Risk: < 0.02% risk of ci-TBI

#### Clinical decision-making factors in favor of:

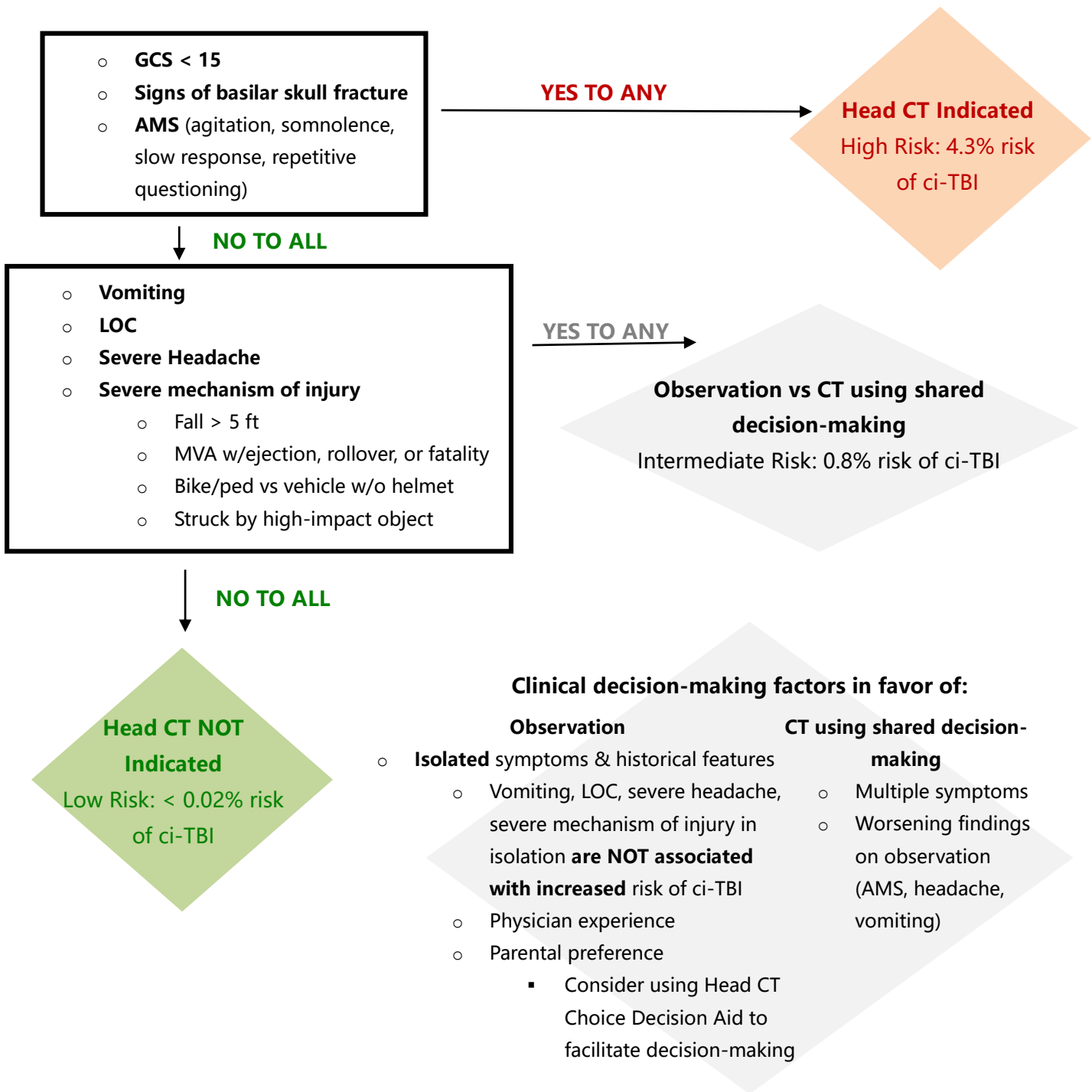
##### Observation

- **Isolated** symptoms & historical features
  - Vomiting, LOC, severe headache, severe mechanism of injury in isolation **are NOT associated with increased** risk of ci-TBI
  - Physician experience
  - Parental preference
    - Consider using Head CT Choice Decision Aid to facilitate decision-making

##### CT using shared decision-making

- Multiple symptoms
- Worsening findings on observation (AMS, headache, vomiting)
- <3 months old

# PECARN Pediatric Minor Head Injury CT Guidelines for Children Age 2+ YEARS



## PURPOSE

The purpose of this guideline is to recognize the different physiological and anatomical considerations of the growing child and to highlight the different approach to imaging needed. Also, this guideline will help clinicians dealing with a severely injured child to make imaging decisions. The use of adult protocols is not appropriate as a routine investigation in childhood.

## POLICY STATEMENTS

All examinations using ionizing radiation should be performed only when necessary to answer a medical question help treat a disease, or guide a procedure. The clinical indication and patient medical history should be carefully considered before referring a patient for any imaging examination.

Exposure to ionizing radiation should always be kept to a minimum in the injured child and imaging examinations should use techniques that are adjusted to administer the lowest radiation dose that yields an image quality adequate for diagnosis or intervention.

The increased risk from ionizing radiation in children is due to a number of factors. Developing and maturing tissues in the growing child are more radiosensitive, there is a cumulative lifelong radiation risk, and they have a longer life time in which to express the increased relative risk.

The injury pattern in children is typically isolated to one anatomical area rather than multiple sites. It is important to appreciate this pattern of potential injury when considering the need for imaging.

If CT is deemed most appropriate investigation, use appropriate dose reduction procedures. The radiation dose should be adjusted according to the "as low as reasonably achievable" (ALARA) principle. Blank Children's Hospital radiology department has a dedicated pediatric protocol that minimizes radiation in children while optimizing imaging quality.

**While "pan-scan" use is widely accepted in adult trauma patients, children are more vulnerable to affects of radiation, and non-selective imaging rarely yields information that changes management or outcome in pediatric patients.**

## **SEDATION FOR PEDIATRIC PATIENT IMAGING**

To help minimize risk of repeat imaging while obtaining high quality radiographic studies, sedation should be considered for a child depending on physiological parameters, age, size, and cognitive level. During initial trauma evaluation, the trauma surgeon and pediatric emergency physician will collaborate to determine the appropriate need for sedation and monitoring. For follow up imaging after admission, the pediatric sedation team should be consulted.

## CHOICE OF IMAGING MODALITY

### **Cranial imaging**

CT is the primary investigation for cranial imaging in a child who has suffered head trauma. Fulfilling the criteria for a head CT scan is not an indication on its own for a CT of the cervical spine or any other part of the body in the injured child.

The PECARN (Pediatric Emergency Applied Care Network) Algorithm is a clinical decision rule that aims to identify children at very low risk of clinically important traumatic injury. The following validated pediatric algorithm should be used to guide the physician for use of head CT.

### **Cervical spine imaging**

See Pediatric Cervical Spine Evaluation and Clearance Guideline and Algorithms

### **Imaging of the spine**

CT of the spine is the gold standard imaging modality to rule out spine injury. CT of the thoracic and

lumbar spine is included in a CT of chest, abdomen and pelvis and targeted CTs of the spine are **NOT** required if these scans are obtained. If there is definitive neurological signs, the primary imaging modality should be MRI.

### **Imaging of the chest**

The primary investigation for blunt chest trauma in children is chest x-ray. This will detect pneumothorax, hemothorax, rib fractures, gross mediastinal abnormalities and diaphragmatic injuries.

Penetrating trauma is an indication for contrast-enhanced chest CT due to the incidence of occult vascular injury.

In blunt trauma while chest CT identifies more injuries, it rarely produces change in clinical management. Most clinically relevant chest injuries and interventions can be determined by clinical exam, hemodynamics, and chest x-ray. Chest CT use has been advocated in adult blunt trauma as they have higher incidence of aortic injuries. However, pediatric patients have different pattern of injury, and aortic injury is rare in children.

### **Imaging of the abdomen**

The use of FAST in children is only recommended if the child is in shock or when CT is unavailable or not feasible. The sensitivity and specificity of FAST are less in children than adults.

If clinically indicated, contrast-enhanced CT is the modality of choice for assessment of acute traumatic intra-abdominal injury.

For follow-up CT in renal injuries when excretory phase imaging is indicated, consider a split dose contrast technique (70/30) to obtain nephrographic/venous and delay excretory phase information in a single acquisition, thereby reducing radiation exposure compared to separate phase acquisition.

There are no mechanisms of injury which mandate abdominal CT as an isolated factor. Isolated head injury with depressed mental status should not be the only justification for abdominal CT. The decision to perform abdominal CT should be made on the basis of the clinical history and examination.

To further guide evaluation of pediatric patients with abdominal traumas see Blunt Abdominal Trauma Evaluation and Management Guideline.

### **Imaging of the limbs**

Using clinical history and examination, clinicians should request plain radiographs of the injured regions as the primary investigation. This usually includes anteroposterior and lateral views including the adjacent joints. CT may be required for complex fractures and CTA for injuries with high suspicion of vascular injury.

### **Imaging of the pelvis**

Pelvis fractures are rare in children. A screening pelvic radiograph is not indicated in all cases. Pelvic imaging should only be considered if there are concerns after clinical assessment. CT of abdomen and pelvis is recommended for pediatric patients with complicated pelvic fracture patterns.

CT of pelvis with bladder contrast is indicated in patients with pelvic fracture and gross hematuria to rule out bladder injury.

Pelvic angiography and embolization can be indicated in cases of pelvic changes and hemodynamic instability or evidence of continued bleeding. CT with IV contrast can assess for sites of active bleeding and help in determining the necessity for embolization as well as pre-procedural planning.

### **Interventional radiology**

Interventional radiology is available when indicated for pediatric patients at Blank Children's Hospital.

**References:**

ACS TQIP. (2018). Best Practices Guidelines. Imaging Guidelines. American College of Surgeons.

Pediatric Trauma Society. Pediatric Thoracic Imaging Assessment in the Setting of Blunt Trauma. Pediatricsociety.org, 2024.

Pediatric Trauma Society. Pediatric Pelvic Fractures. Pediatricsociety.org, 2024.

The Royal College of Radiologist. Pediatric trauma protocols. London: The Royal College of Radiologist, 2014.

U.S Department of Health and Human Services, U.S. Food and Drug Administration. Initiative to Reduce Unnecessary Radiation Exposure from Medical Imaging. 02/27/2017

Rozzelle CJ, Aarabi B, Dhall SS, Gelb DE, Hurlbert RJ, Ryken TC, Theodore N, Walters BC, Hadley MN. Management of pediatric cervical spine and spinal cord injuries. Neurosurgery. 2013 Mar; 72 Suppl 2:205-26.